

2026 WINNIPEG VASCULAR AND ENDOVASCULAR SYMPOSIUM

Kirk Lawlor BSc, MD, MEd, FRCSC, FACS

Head, Division of Vascular Surgery

Vancouver General Hospital and University of British Columbia



COMPLICATION OF TRANSPLANT

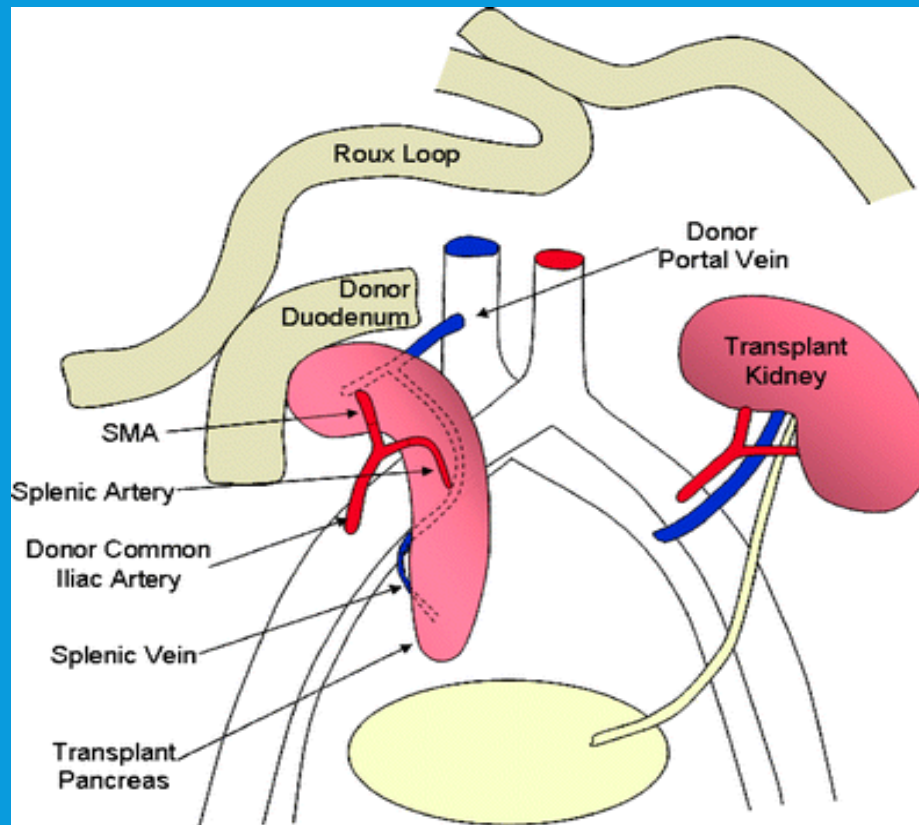
COMBINED LIVER AND PANCREATIC TRANSPLANT MARCH 2025

- 34 yo F Type I DM
- CKD on HD since April 2022
- Neuropathy, gastroparesis, retinopathy

COMBINED KIDNEY AND PANCREATIC TRANSPLANT MARCH 2025

- Simultaneous deceased donor kidney/pancreas transplant
- Left external iliac artery/vein for pelvic kidney transplant.
- Pancreas and duodenum transplant to right iliac system and Roux-en-Y

COMBINED LIVER AND PANCREATIC TRANSPLANT MARCH 2025



POST-OP

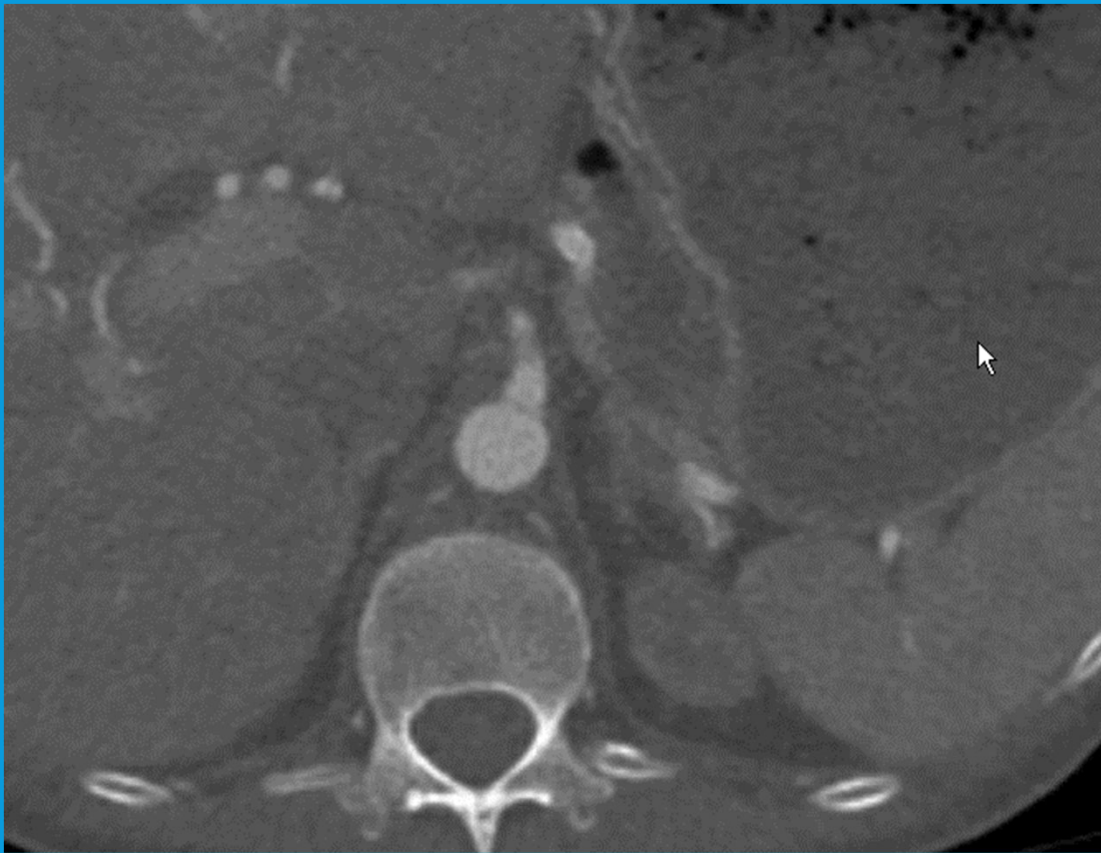
- Uneventful
- Tacrolimus, Mycophenolate, Prednisone, Septra, Vancyclovir
- POD 14 Creat 71, BS 4.8. NO INSULIN
- Discharged

POST-OP COURSE

- Readmitted June with delayed gastric emptying and anemia
- Parvovirus B19. IVIG 5 courses
- 2 recurrent episodes associated with abd pain.

- November E coli UTI. Fort St John
- Right leg pain, paresthesias, transferred
- Nov 30 Rutherford IIB ischemia right leg

CT NOVEMBER 29, 2025



- Right CI aneurysm with thrombosis below transplant graft anastomosis
- Right EI occlusion

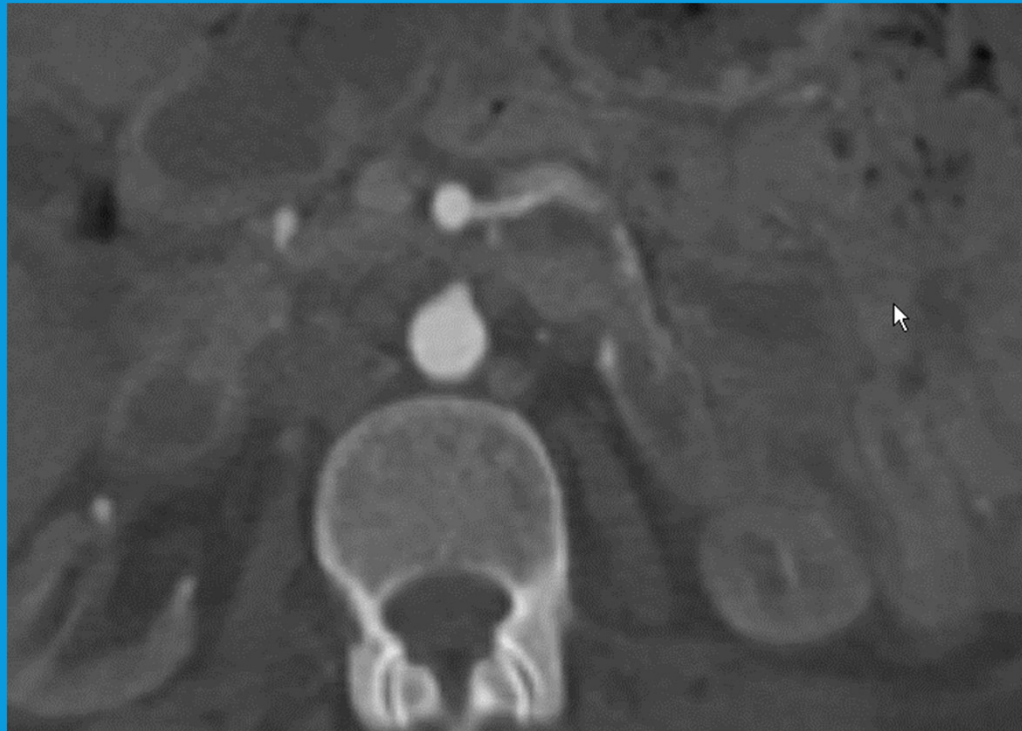
OR NOVEMBER 30, 2025

- Right ileo femoral thromboembolectomy and fasciotomy
- Uneventful post op

POST-OP NOVEMBER 30, 2025

- Mycotic right iliac aneurysm?
- C&S from thrombectomy *Serratia marcescens*
- Pip/Taz changed to meropenem 6 weeks.
- F/U CTA

CT DECEMBER 3, 2025



OR.....NOW WHAT?

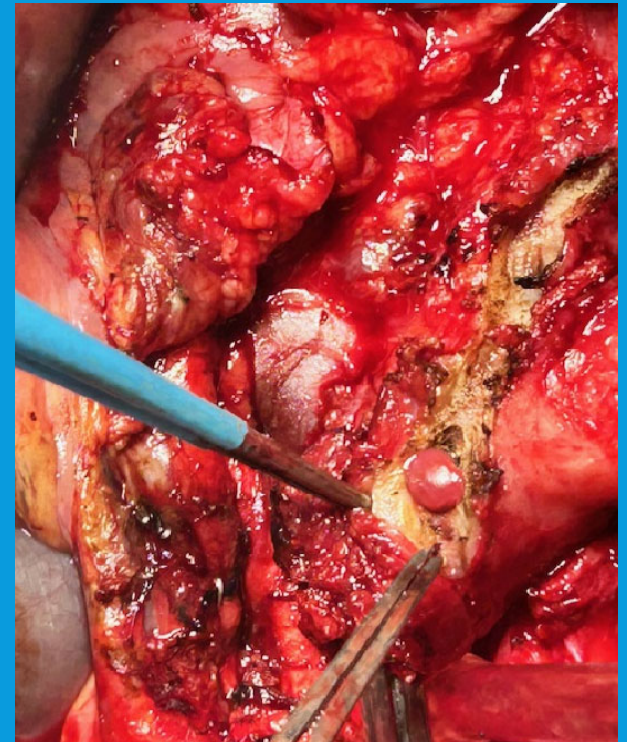- Pancreatectomy?
- Nephrectomy?
- In line Reconstruction?
- Extraanatomic?
- Conduit?

OR.....NOW WHAT?

- Discussed ID, Endocrine, HPB,Tx Nephro

OR- DEC 5, 2025

- Fem-fem bypass
- Left SFV graft
- Pancreatectomy
- Resection right CI artery and aneurysm/phlegmon
- Preserved kidney Tx



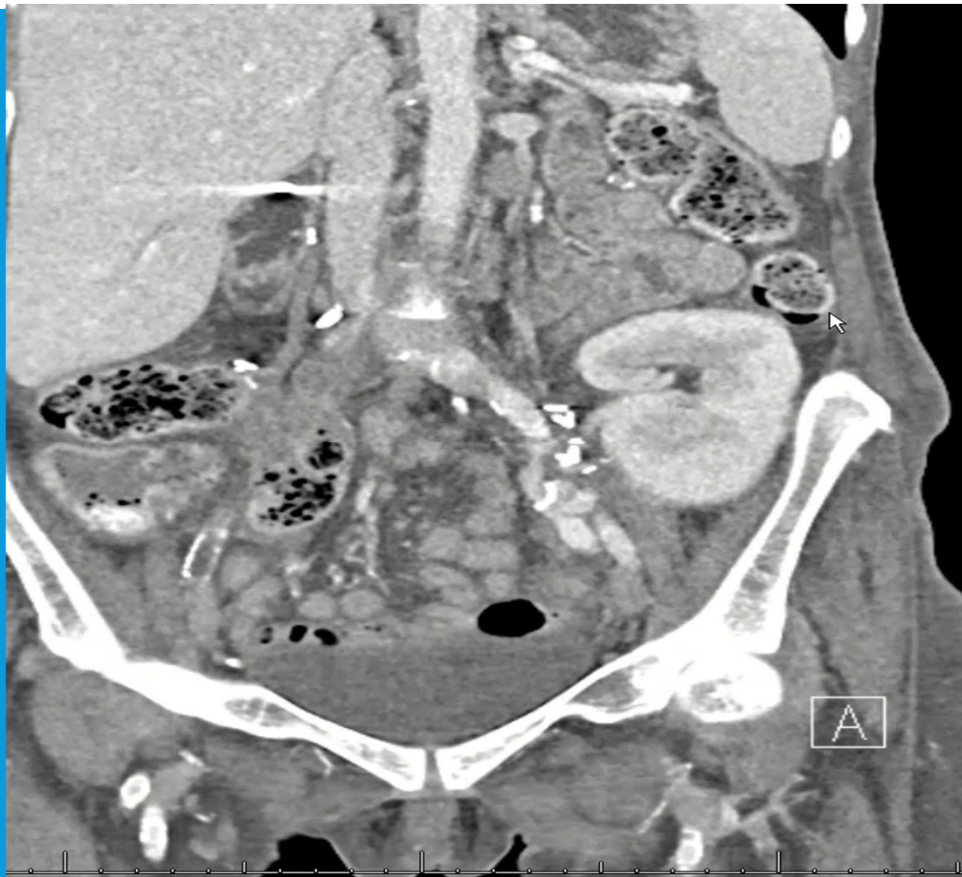POST-OP

- Back on Insulin BS 4-11
- Creat 68
- Legs OK

POST-OP

- Post-op 4 weeks
- Prednisone 5mg, tacrolimus 0.5 IV bid, MMF IV 500mg bid
- WBC 2.2 ANC 1.0
- Groin incisions still not healed from December
- CT F/U

CT JANUARY 23, 2026



New mycotic aneurysm

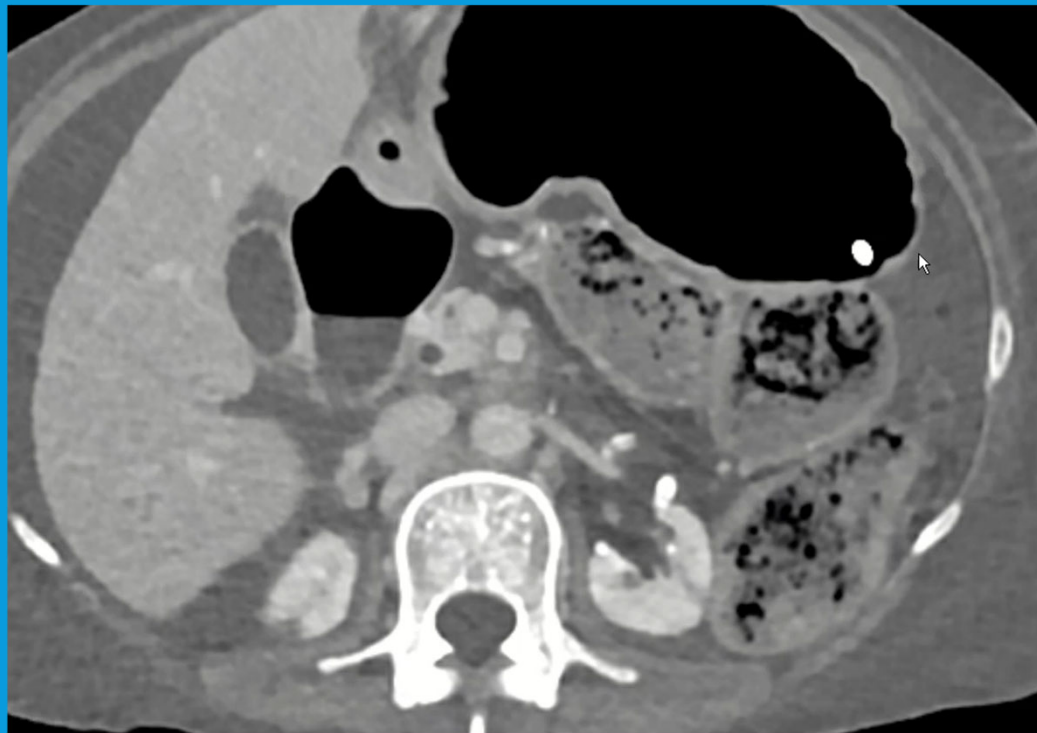
NOW WHAT ????

- IV Meropenem/ Decrease Immunosuppression
- Transplant nephrectomy? (allow discontinue immunosuppression)
- Inline aorto-left iliac reconstruction? Conduit?
- Left Ax-Fem?

OR JANUARY 26, 2026

- Right SFV(6mm) (Can't do end-end and not enough length for panel)
- Infrarenal aorta(end-side) to distal left CI(end-end)
- Oversee mid infrarenal aorta below anast and excise distal aorta and bifurcation

CT F/U FEBRUARY 14, 2026



FOLLOW-UP

- GFR 65
- IDDM
- Tacrolimus 25mg bid, prednisone 5mg od
- 6 weeks IV meropenem